

CASE REPORT

Bilateral Bifid Mandibular Condyle: A Rare Case Report and Review

¹Mahesh TS Kumar, ²Rajeshwari K, ³Manjunath N, ⁴Naveen N Kumar

ABSTRACT

Bifid mandibular condyle is described in the literature as a very rare entity, often diagnosed on routine radiographic examination. The incidence of this condition was found to be 0.018%. Till date, less than 50 cases have been reported in the literature among patients with bifid mandibular condyle. The cause for this condition still remains controversial. Most of the time, this condition is asymptomatic and does not require any treatment. But symptomatic cases may require advanced imaging and treatment like occlusal splints and arthroscopic surgery. Herein we report a rare case of bilateral bifid mandibular condyle in a 34-year-old male patient.

Keywords: Bifid condyle, Duplication of condyle, Panoramic radiograph.

How to cite this article: Kumar MTS, K Rajeshwari, N Manjunath, Kumar NN. Bilateral Bifid Mandibular Condyle: A Rare Case Report and Review. *Int J Prev Clin Dent Res* 2016;3(1):42-44.

Source of support: Nil

Conflict of interest: None

INTRODUCTION

Bifid mandibular condyle (BMC) is an uncommon anomaly presenting as a vertical depression or deep cleft in the middle of the condylar head in the anteroposterior or mediolateral plane.¹ Duplication of mandibular condyle is one of the rarest anomaly with an unclear etiology. Szentpetery et al² found the incidence of BMC to be 0.48% in 1,882 cadaveric skulls.

Even though the etiology of BMC is unclear, the other cited possible causes could be secondary to trauma, obstructed blood supply or embryopathy, developmental anomalies, secondary to condylar fracture, perinatal trauma, and surgical condylectomy.¹ With this background, we report a rare case of bilateral BMC in a 34-year-old male patient.

CASE REPORT

A 34-year-old male patient reported to the Department of Oral Medicine and Radiology with a chief complaint of deposits over the teeth. On clinical examination, the patient was moderately built and nourished; vital signs were within normal limits. Gross facial asymmetry was observed on the right side (Fig. 1). Deviation of the jaw toward left side was observed with a normal mouth opening. Intraoral examination revealed presence of supragingival and subgingival calculus, generalized pockets, and bleeding on probing. Based on the history and clinical examination, a provisional diagnosis of chronic generalized periodontitis was arrived and patient was subjected to screening radiographs like orthopantomograph and blood investigations.

Orthopantomograph (Fig. 2) revealed presence of horizontal bone loss in relation to 16, 17, 18, 27, 28, 36, 37, 38, 44, 45, 46, 47, 48, which was about 3 mm below the cemento-enamel junction. In relation to 34, the bone loss was extending till the root apex. There was an increased density observed in both the condyles with duplication

^{1,2,4}Senior Lecturer, ³Professor

¹Department of Oral Medicine and Radiology, Rajarajeswari Dental College and Hospital, Bengaluru, Karnataka, India

²Department of Oral Medicine and Radiology, AECS Maruti College of Dental Sciences and Research Centre, Bengaluru Karnataka, India

³Department of Oral Medicine and Radiology, Al Badar College of Dental Sciences, Kalaburagi, Karnataka, India

⁴Department of Oral Medicine and Radiology, Vydehi Institute of Dental Sciences and Research Centre, Bengaluru, Karnataka India

Corresponding Author: Mahesh TS Kumar, Senior Lecturer Department of Oral Medicine and Radiology, Rajarajeswari Dental College and Hospital, Bengaluru, Karnataka, India Phone: +919916224401 e-mail: mahesh_talkad@yahoo.co.in

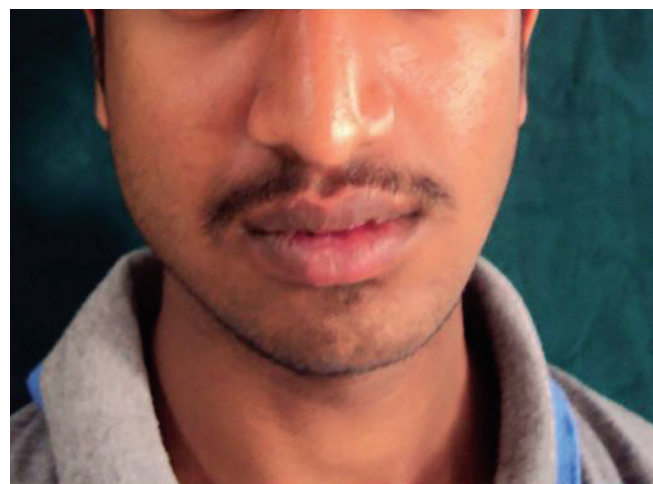


Fig. 1: Frontal view

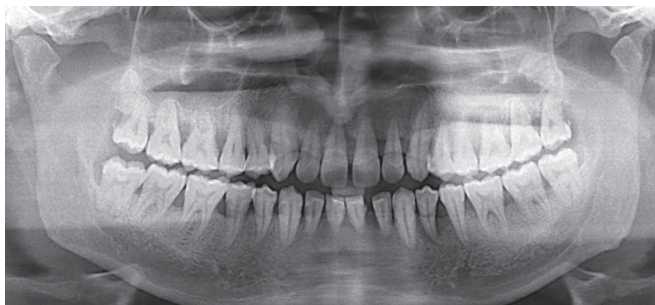

Fig. 2: Panoramic radiograph showing bifid mandibular condyle

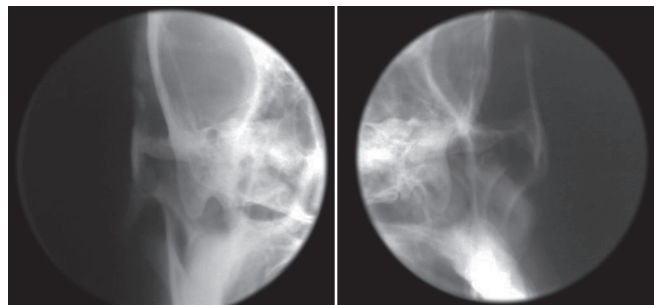


Fig. 3: Right and left transorbital temporomandibular joint views showing bifid mandibular condyle

of the condylar head. A radiographic diagnosis of chronic generalized periodontitis and BMC was given.

Malunited condylar fracture was considered under differential diagnosis for BMC. Later the patient was subjected to transorbital temporomandibular joint (TMJ) projections (Fig. 3), the left side condyle showed a depression over the superior surface of the condylar head giving the anteroposterior silhouette a heart-shaped radiopaque structure suggestive of bifid condyle. On the right side, the condylar head was uniformly convex in the superior aspect. These findings confirmed the diagnosis as BMC on both the sides. Based on the history, clinical examination, and investigations, a final diagnosis of chronic generalized periodontitis and bilateral BMC was given. Patient was subjected to periodontal therapy and oral hygiene instructions were given. For the bifid condyle, no treatment was advised since the patient was asymptomatic.

DISCUSSION

Bifid mandibular condyle is an unusual anomaly that has a vertical groove or deep cleft in the center of the condylar head in the anteroposterior or mediolateral plane.¹ It can be developmental or acquired in origin. Rarely, it can occur in association with TMJ ankylosis. Hrdlička in 1941³ reported for the first time in the history about BMC in skeletal specimens. Later on, the first report of this condition was made by Schier in 1948⁴ in a living population. On examining 50,080 orthopantomographs, in 2008, Menezes et al⁵ found BMC in about 9 (0.018%) cases among Brazilian population.

The two major causes of BMC could be either traumatic or developmental. It has been reported that, among the living subjects, BMC falls within one of the following causes: Those with history of trauma and those without.⁴

In maximum number of cases, the cause of BMC remains unknown, although several factors have been recommended as possible causes, that can be secondary to endocrine disturbances, exposure to teratogens, nutritional deficiencies, infections, and radiation exposure.⁶

It was stated by Blackwood that, at the early stages of the development of the condyle, the condylar cartilage is divided by a well-vascularized fibrous septa. He also recommended that, within the growing cartilage, remnants of this type of septa in an exaggerated form could lead to a malformation in the condyle which in turn leads to bifid condition.⁷

Concerning BMC, it was found that there is no age predilection. The age of the patients may range from 3 to 67 years (mean age being 35 years) and the male to female ratio is approximately 1.5:1. The left side of the mandible is affected more than the right side.⁸ The present case was seen in a 35-year-old male patient and it involved both sides of the mandible.

The most commonly associated symptoms are clicking sounds in TMJ, pain, restricted mandibular movements, trismus, swelling, ankylosis, and facial asymmetries. In the present case, the patient had gross facial asymmetry with no other symptoms. The diagnosis of bifid condyle is purely based on its radiographic appearance, which is almost always found by chance. The bifid condyle may be discovered on routine dental radiographic examination or during the investigation of some other problem.⁹ Even the present case was discovered on taking a panoramic radiograph while investigating for the periodontal issues.

Treatment of BMC usually depends on the presenting complaints of the patient. However, symptoms are not observed in the affected condyle in about 67% of patients with BMC.¹⁰ In the present case, as the patient did not have any other symptoms related to condyles, no treatment was advised in relation to the bifid condyle. The patient was informed about the changes in the condyles and long-term follow-up was recommended in case of development of potential subsequent clinical symptoms. Patient was recalled and reviewed every 6 months for any symptoms, but even after 2 years of the initial visit, no symptoms were reported. In symptomatic cases, the treatment depends on presenting complaints of patient. In the presence of any articular derangement, occlusal splints and arthroscopic surgery can be a treatment choice. But articular ankylosis may need surgical condylectomy or arthroplasty.

CONCLUSION

We conclude that BMC remains a rare condition since it remains asymptomatic in most of the cases. It is believed that BMC is an incidental finding upon routine radiographic examination rather than a clinical observation. So a thorough clinical examination and radiological examination should be performed in suspected cases for better diagnosis. This condition can be considered under differential diagnosis of facial asymmetries and TMJ disorders. Most of the time, this condition does not require any treatment unless it is symptomatic. In such cases, the patients should be subjected to further investigations like computerized tomography scan and magnetic resonance imaging for a prompt diagnosis and are treated by occlusal splints and arthroscopic surgery.

REFERENCES

1. White, SC.; Pharoah, MJ. Oral radiology: principles and interpretation. 6th ed. St Louis, MO: Elsevier;2009. p. 485.
2. Szentpetery A, Kocsis G, marcsik A. The problem of the bifid mandibular condyle.J. Oral Maxillofac Surg 1990;48: 1254-1257.
3. Hrdlička A. Lower jaw: double condyles. Am J Phys Anthropol 1941 Mar;28(1):75-89.
4. Schier MBA. The temporomandibular joint: a consideration of its probable functional and dysfunctional sequelae and report: condyle-double in a young person. Dent Items Interest 1948 Oct;70(10):1095-1109.
5. Menezes AV, de Moraes Ramos FM, de Vasconcelos-Filho JO, Kurita LM, de Almeida SM, Haiter-Neto F. The prevalence of bifid mandibular condyle detected in a Brazilian population. Dentomaxillofac Radiol 2008 May;37(4):220-223.
6. Balciunas BA. Bifid mandibular condyle. J Oral Maxillofac Surg 1986 Apr;44(4):324-325.
7. Blackwood HJ. The double-headed mandibular condyle. Am J Phys Anthropol 1957 Mar;15(1):1-8.
8. Antoniadis K, Karakasis D, Elephteriades J. Bifid mandibular condyle resulting from a sagittal fracture of the condylar head. Br J Oral Maxillofac Surg 1993 Apr;31(2):24-26.
9. Shaber EP. Bilateral bifid mandibular condyles. Cranio 1987 Apr;5(2):191-195.
10. Loh FC, Yeo JF. Bifid mandibular condyle. Oral Surg Oral Med Oral Pathol 1990 Jan;69(1):24-27.